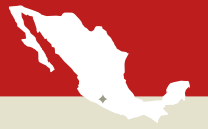


Eucharistic Miracle of TIXTLA

MEXICO, OCTOBER 21, 2006

1



On October 12, 2013, H.E. Most Rev. Alejo Zavala Castro, Bishop of the Diocese of Chilpancingo-Chilapa, announced through a Pastoral Letter the recognition of the Eucharistic Miracle that occurred at Tixtla, on October 21, 2006. In the letter we read: “This manifestation brings to us a marvelous sign of the love of God that confirms the Real presence of Jesus in the Eucharist... In my role as Bishop of the Diocese I recognize the supernatural character of the series of events relating to the Bleeding Host of Tixtla... I declare the case as a “Divine Sign ...”.



On October 21, 2006, the *effusion of a reddish substance* was noted from a consecrated Host during the Eucharistic Celebration at Tixtla, in the Diocese of Chilpancingo-Chilapa. The Bishop of the place, Most Reverend Alejo Zavala Castro, then convened a Theological Commission of investigation and, in October 2009, he invited Doctor Ricardo Castañón Gómez, to take on the leadership of the program of scientific research whose purpose was in fact that of verifying the said event. The Mexican Ecclesiastical authorities turned to Doctor Castañón Gómez because they were aware that, in the years 1999-2006, the scientist had conducted some studies on two consecrated Hosts that also bled in the Parish of Saint Mary, in Buenos Aires. The Mexican case starts in October 2006, when Father Leopoldo Roque, pastor of the Parish of Saint Martin of Tours, invites Father Raymundo Reyna Esteban to lead a spiritual retreat



for his parishioners. As Father Leopoldo and another priest were distributing Communion, assisted by a religious sister who was to the left of Father Raymundo, this latter one turns towards him with the “pix” containing the Sacred Particles, looking at Father with eyes filled with tears, an incident that immediately attracted the attention of the celebrant: the Host that she had taken to give Communion to a lady parishioner had begun to effuse a reddish substance.

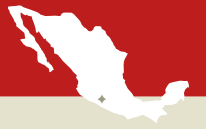

The Host which bled

Eucharistic Miracle of TIXTLA

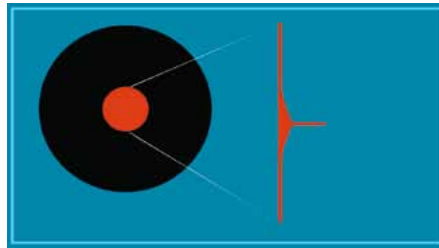
MEXICO, OCTOBER 21, 2006

2

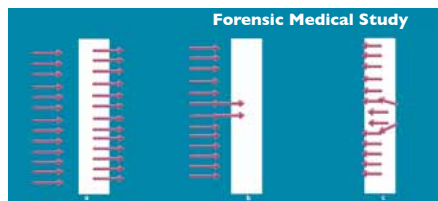


“The ecclesiastical authority wanted likewise to specify that in a Catholic context the Miracle distinguishes itself for the following aspects:

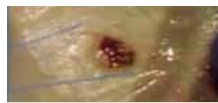1. Theological:
The intervention comes from God. It is of divine origin.
2. Objectivity:
The ‘alteration’ of the causes or natural laws is evident.
3. Subjectivity:
Whoever accepts the miracle ‘recognizes or accepts’ with an act of Faith that the extraordinary event comes from the loving Will of God.
4. Purpose:
It has as its end the good of one or many people.”



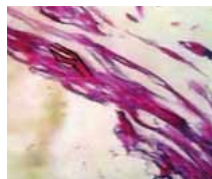
Graphic which illustrates how the blood flowed from the interior of the host towards the exterior, as it occurs with a wound.



Within the graphic, in the drawing c it is seen clearly how the flow of blood occurred, from the interior towards the exterior. In the drawing a it is seen how it would have been if someone had inserted some blood from the exterior. It would have expanded into all the channels. There is no situation b in which someone could put some liquid which entered only through two channels and the rest remaining on the surface without being absorbed.




By analyzing the Host it was observed that it was human blood of type AB and that it corresponded to tissue. Then an analysis was done of phytochemical markers which confirmed that it was live cardiac muscle. No study exists that can maintain alive a cardiac tissue in this situation. Normally after 48 hours the tissue dies, here 3 months passed before the result could be obtained and this is truly unexplainable for science.



Professor Carlos Parellada, of the Francisco Marroquín University in Guatemala, shows in one of the photos taken of the sample of the miraculous Host, how the presence of longitudinal fibrillar structures is evident. By observing the image one sees well the bifurcation that was made evident, which is typical of the muscular cardiac fiber, that is of the heart.



In 2010, by means of a study of digital microscopic penetration through the shooting of ultraviolet rays and intense white light it was demonstrated that the tissue seen in the upper part of the Host showed some dry coagulated blood. The analyses showed moreover that under the Blood already coagulated beyond some structures of the white Host, there was also the presence of fresh Blood. Also this analysis confirmed the fact that the blood was not placed by someone from the exterior because if it were like this it could not remain fresh for so much time (from 2006 to 2010) only in the internal part of the Host.



Professor John Compagno, one of the preminent histopathologists who study tissues, discovered that there was the presence of mesenchymal cells and of tissue of white blood cells and red blood cells, but to arrive to say that it was heart muscle further exams had to be done and the result arrived only after 2 years.



Photo of Father Raymondo Reyna Esteban, protagonist of the Eucharistic Miracle of Tixtla.

The Gene Ex genetics laboratory in Bolivia performed another study and confirmed that it was human blood of the type AB just like the one found in the cloth of the Shroud of Turin and of the Eucharistic Miracle that occurred in Lanciano in 700 AD.

The scientific research conducted between October 2009 and October 2012 came to the following conclusions, presented on May 25, 2013 during the course of an international Symposium held by the Diocese of Chilpancingo, on the occasion of the Year of Faith, and which saw the participation of millions of people coming from four continents

1. The reddish substance analyzed corresponds to blood in which there are hemoglobin and DNA of human origin.

2. Two studies conducted by eminent forensic experts with different methodologies have shown that the substance originates from the interior, excluding the hypothesis that someone could have placed it from the exterior.


3. The blood type is AB, similar to the one found in the Host of Lanciano and in the Holy Shroud of Turin.

4. A microscopic analysis of magnification and penetration reveals that the superior part of the blood has been coagulated since October 2006. Moreover, the underlying internal layers reveal, in February 2010, the presence of fresh blood.

5. They also found intact white blood cells, red blood cells, and active macrophages that engulf lipids. The tissue in question appears lacerated and with recovery mechanisms, exactly as occurs in a living tissue.

6. A further histopathological analysis determines the presence of protein structures in a state of deterioration, suggesting mesenchymal cells, very specialized cells, characterized by an elevated bio-physiological dynamism.

7. The immunohistochemical studies reveal that the tissue found corresponds to the muscle of the heart



When there is the presence of human DNA one thinks that also the genetic profile can be automatically obtained. Interestingly in all the studies performed on the images that showed blood or in the consecrated Hosts that have bled the presence of DNA was found, but when the work of sequencing to extract the genetic profile was done, they were never able to obtain it. The theologians say that since Jesus does not have a father, his father is the Holy Spirit, it is not possible to obtain his genetic profile.

(Myocardium). On account of the scientific results and the conclusions reached by the theological committee, last October 12 the Bishop of Chilpancingo, his Eminence Alejo Zavala Castro, announced the following:

- The event does not have a natural explanation.
- It does not have paranormal origin.
- It is not traceable to manipulation of the enemy.”